

Postoperative Pseudomeningocele: A Rare Complication of Lumbar Spine Surgery

TUSHAR KALEKAR¹, NIHARIKA PRASAD², BHAVYA DANG³**Keywords:** Lower back pain, Magnetic resonance imaging, Meningeal pseudocyst

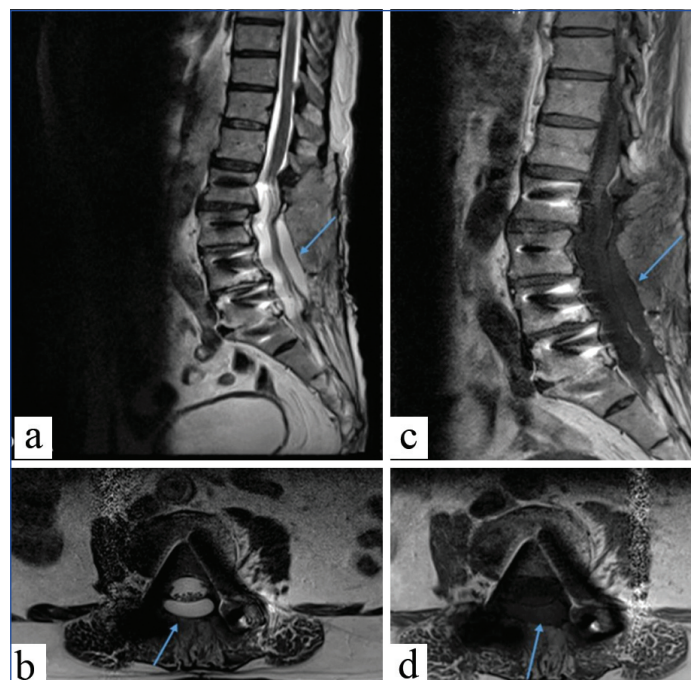
A 64-year-old male with a history of chronic lower back pain for the past three years, which had progressively worsened over the preceding month and led to difficulty in walking, presented with associated tingling sensations in the left lower limb for two years and urinary incontinence for one week. He was evaluated clinically and radiologically and diagnosed with multilevel lumbar canal stenosis and degenerative spondylolisthesis. There was no history of trauma, fever, constitutional symptoms, or bowel disturbances. The patient was known to be hypertensive, non diabetic and a non smoker and had no prior history of spinal trauma or tuberculosis.

He underwent L2-L4-L5-S1 bilateral pedicle screw fixation, L3 pedicle screw fixation and L3-S1 laminectomy with bilateral nerve root decompression. Two months after surgery, he presented to the Department of Neurology with complaints of persistent lower back pain and a progressive, fluctuant swelling at the prior surgical site. The pain radiated to both lower limbs and was associated with tingling and numbness in the left lower limb. He denied motor weakness or bowel/bladder dysfunction at the time of presentation and was referred to the Department of Radiodiagnosis for Magnetic Resonance Imaging (MRI) evaluation.

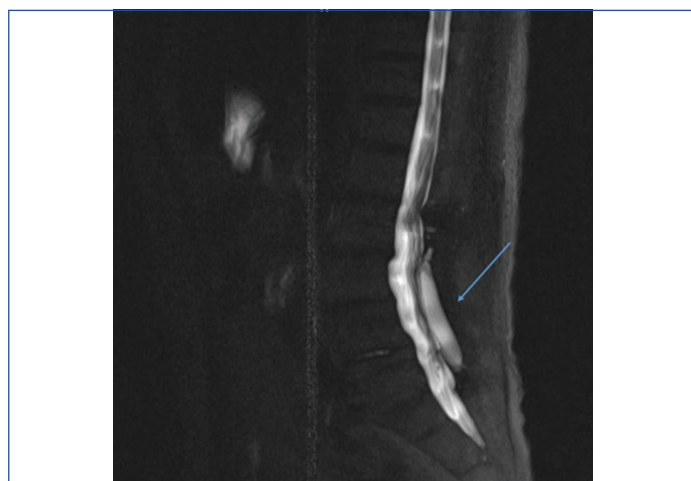
On physical examination, a fluctuant, non pulsatile, non tender swelling measuring approximately 6x2.5 cm was noted in the lower lumbar midline scar region. The swelling was oval, non mobile, soft and transilluminant, with no overlying erythema, warmth, or signs of local infection. The neurological examination revealed normal motor strength with decreased superficial sensation in the left L4-L5 dermatomes. Deep tendon reflexes were diminished in the lower limbs. The straight leg raise test was positive on the left and pain was exacerbated by Valsalva manoeuvres, such as coughing and sneezing.

A postoperative Magnetic Resonance Imaging (MRI) scan of the Lumbosacral (LS) spine revealed a well-defined Cerebrospinal Fluid (CSF) intensity collection {hyperintense on T2-weighted imaging [Table/Fig-1a,b] and hypointense on T1-weighted imaging [Table/Fig-1c,d]}, measuring 21x10x61 mm. This collection extended from L3 to L5, posterior to the dura, consistent with a pseudomeningocele – a rare complication of spinal surgery caused by an unsealed dural defect and persistent CSF leakage. Furthermore, a single-slice MR myelogram [Table/Fig-2] demonstrated the continuity of the pseudomeningocele with the thecal sac (blue arrow), extending from L3 to L5, further confirming the diagnosis. Additional findings included posterior tethering of the cauda equina nerve roots at the L3, L5 and S1 levels, as well as susceptibility artefacts from transpedicular screws at the L1, L3, L4 and L5 vertebrae.

The differential diagnoses for postoperative fluid collections include seroma, which appears as a homogeneous simple fluid collection without neural symptoms; haematoma, which is hyperintense on T1-weighted imaging with blooming on Gradient Echo (GRE) sequences and usually has an acute onset; and abscess, which typically shows inhomogeneous signals with rim enhancement and may be associated with discitis or osteomyelitis.



[Table/Fig-1]: MRI of the Lumbosacral (LS) spine: T2-weighted images (a- sagittal, b- axial) and T1-weighted images (c- sagittal, d- axial) shows a well-defined CSF-intensity collection extending from L3 to L5, posterior to the dura, suggestive of a postoperative pseudomeningocele (blue arrows). The sac does not contain neural elements. Loss of lumbar lordosis and susceptibility artifacts from transpedicular screws are also noted.



[Table/Fig-2]: A single-slice MR myelogram shows the continuity of the pseudomeningocele with the thecal sac (blue arrow) extending from L3 to L5.

Given the absence of significant neurological deficits and the stability of the collection, a conservative approach was adopted. The patient was managed with analgesics, bed rest, lumbar support and clinical monitoring. Over a six-week follow-up period, the swelling regressed and symptoms improved. No surgical reintervention was required. He continues to be followed-up in the outpatient department and remains neurologically stable.

A pseudomeningocele, also known as a meningeal pseudocyst, is a fistula or accumulation of CSF that can arise from the extravasation of CSF caused by a dural or arachnoid tear during surgery. Three types of pseudomeningoceles have been reported in the literature: traumatic, postoperative and congenital [1]. According to research by Swanson HS and Fincher EF [2] and Teplick JG et al., [3], the incidence of postoperative pseudomeningocele in patients who have undergone lumbar laminectomy varies between 0.07% and 2%. Patients may present with a wide range of symptoms, some of which may not appear for years [1]. Usually, a pseudomeningocele presents as low back pain that worsens during coughing and sneezing. When nerve roots in the cyst cavity herniate, patients may also exhibit radicular symptoms. Rarely, individuals may demonstrate sphincter dysfunction and motor impairments.

The MRI is the recommended method for detecting pseudomeningoceles in postoperative patients. MRI frequently shows a fluid collection of varying size with CSF intensity along the surgical path, which may or may not be contained by the deep muscle fascia. A pseudomeningocele is characterised by a hypointense lesion on T1-weighted scans and a hyperintense lesion on T2-weighted sequences. Correlation with clinical information is critical for detecting a postoperative pseudomeningocele, since its imaging characteristics are similar to those of a seroma and, to a lesser extent, a growing liquid haematoma or abscess. On MRI, both haematomas and abscesses exhibit complex signals, are inhomogeneous, possess larger enhancing borders or capsules and abscesses are likely associated with discitis and/or osteomyelitis. A haematoma exhibits "blooming" on T2* (GRE) sequences.

Up to this day, only a limited number of studies have addressed the occurrence and management of lumbar postoperative pseudomeningoceles [4-7]. The first such report was published by Hyndman OR and Gerber WF in 1946, recognising the complication as a result of unsealed dural tears during spinal procedures [8]. Raudenbush BL et al., later described three cases where compressive pseudomeningoceles were associated with neurological deficits; these cases were managed successfully with surgical decompression and dural repair [4]. Conversely, Solomon P et al., documented four patients with large pseudomeningoceles that resolved without surgical intervention, highlighting the potential for spontaneous healing in asymptomatic cases [5]. Gupta R and Narayan S reported two additional cases where the pseudomeningoceles were managed

operatively; in both instances, the dural defects were clearly visualised and repaired during revision surgery, leading to symptom resolution [6]. Weng YJ et al., also presented a case series involving eleven patients with giant pseudomeningoceles, each measuring between 8 and 11 cm in length, who underwent successful surgical treatment, further emphasising the variability in size and the need for individualised management approaches [7].

Treatment strategies for postoperative pseudomeningoceles continue to be a subject of debate among surgeons. Decisions are largely influenced by the location of the defect, the size of the collection and the presence of associated neurological deficits [9]. Surgical options vary and include direct dural repair, the application of autologous or synthetic patch grafts, the use of fibrin glue, CSF diversion techniques such as lumbar shunts or subarachnoid drains and epidural blood patches [10,11]. In some cases, observation remains a valid option, especially for small and asymptomatic lesions. In the present case, conservative management led to resolution without surgical reintervention, consistent with a similar case reported in the literature [5].

REFERENCES

- [1] Miller PR, Elder FW Jr. Meningeal pseudocysts (meningocele spurius) following laminectomy: Report of ten cases. *J Bone Joint Surg Am* 1968;50(2):268-76.
- [2] Swanson HS, Fincher EF. Extradural arachnoidal cysts of traumatic origin. *J Neurosurg.* 1947;4(6):530-38.
- [3] Teplick JG, Peyster RG, Teplick SK, Goodman LR, Haskin ME. CT identification of postlaminectomy pseudomeningocele. *Am J Roentgenol.* 1983;140(6):1203-06.
- [4] Raudenbush BL, Molinari A, Molinari RW. Large compressive pseudomeningocele causing early major neurologic deficit after spinal surgery. *Global Spine J.* 2017;7(3):206-12.
- [5] Solomon P, Sekharappa V, Krishnan V, David KS. Spontaneous resolution of postoperative lumbar pseudomeningoceles: A report of four cases. *Indian J Orthop.* 2013;47(4):417-21.
- [6] Gupta R, Narayan S. Post-operative pseudomeningocele after spine surgery: Rare cause of failed back syndrome. *Iran J Neurosurg.* 2016;2(1):15-18.
- [7] Weng YJ, Cheng CC, Li YY, Huang TJ, Hsu RWW. Management of giant pseudomeningoceles after spinal surgery. *BMC Musculoskelet Disord.* 2010;11:53.
- [8] Hyndman OR, Gerber WF. Spinal extradural cysts, congenital and acquired: Report of cases. *J Neurosurg.* 1946;3:474-86.
- [9] Rege SV, Harshad P. Iatrogenic lumbar pseudomeningocele: A case report and review of literature. *Int J Med Res Health Sci.* 2016;5(1):153-57.
- [10] Surapaneni S, Hasoon J, Orhurhu V, Viswanath O, Kaye AD, Yazdi C, et al. Presentation and management of a postoperative spinal pseudomeningocele. *Pain Ther.* 2020;9(1):333-35.
- [11] Barber SM, Fridley JS, Konakondla S, Nakhla J, Oyelese AA, Telfeian AE, et al. Cerebrospinal fluid leaks after spine tumor resection: Avoidance, recognition and management. *Ann Transl Med.* 2019;7(10):217.

PARTICULARS OF CONTRIBUTORS:

1. Professor, Department of Radiodiagnosis, Dr. D. Y. Patil Medical College, Hospital and Research Centre, Pune, Maharashtra, India.
2. Assistant Professor, Department of Radiodiagnosis, Dr. D. Y. Patil Medical College, Hospital and Research Centre, Pune, Maharashtra, India.
3. Resident, Department of Radiodiagnosis, Dr. D. Y. Patil Medical College, Hospital and Research Centre, Pune, Maharashtra, India.

NAME, ADDRESS, E-MAIL ID OF THE CORRESPONDING AUTHOR:

Dr. Bhavya Dang,
Resident, Department of Radiodiagnosis, Dr. D. Y. Patil Medical College, Hospital and Research Centre, Pune-411018, Maharashtra, India.
E-mail: bhavyadang1997@gmail.com

AUTHOR DECLARATION:

- Financial or Other Competing Interests: None
- Was informed consent obtained from the subjects involved in the study? Yes
- For any images presented appropriate consent has been obtained from the subjects. Yes

PLAGIARISM CHECKING METHODS: [Jain H et al.]

- Plagiarism X-checker: Apr 01, 2025
- Manual Googling: May 03, 2025
- iThenticate Software: May 05, 2025 (2%)

ETYMOLOGY: Author Origin

EMENDATIONS: 5

Date of Submission: Mar 25, 2025

Date of Peer Review: Apr 18, 2025

Date of Acceptance: May 07, 2025

Date of Publishing: Jul 01, 2025